Complete Interruption Of The Left Hepatic Vein In A Pediatric Trauma Patient

Tolga Canbak [1], Ali Kılıç [1], Ceyhan Şahin [2], Semih Mirapoğlu [2], Gül İlayda Sarar [3], Aylin Acar [1]

[1] University of Health Sciences, Turkey. Umraniye Training and Research Center, General Surgery, İstanbul, Turkey
[2] University of Health Sciences, Turkey. Umraniye Training and Research Center, Pediatric Surgery, İstanbul, Turkey
[3] University of Health Sciences, Turkey. İstanbul Zeynep Kamil Maternity and Children Diseases Health Training and Research Center, Department of Pediatric Surgery, İstanbul, Turkey

Introduction: We aimed to discuss a 15-year-old with stage 5 liver damage requiring emergent laparotomy.

Case presentation: 15-year-old girl was involved in a minibus accident while walking on the street. Focused assessment with sonography in trauma revealed free intraperitoneal fluid. She underwent contrast-enhanced computed tomography scan and found to have grade 5 liver injury with multiple lacerations on the right anterior lobe and almost all of the left lobe, grade 3 right renal injury and displaced left inferior pubic ramus fracture without any other organ damage. Within an hour, emergent laparotomy was performed due to hemodynamic instability.

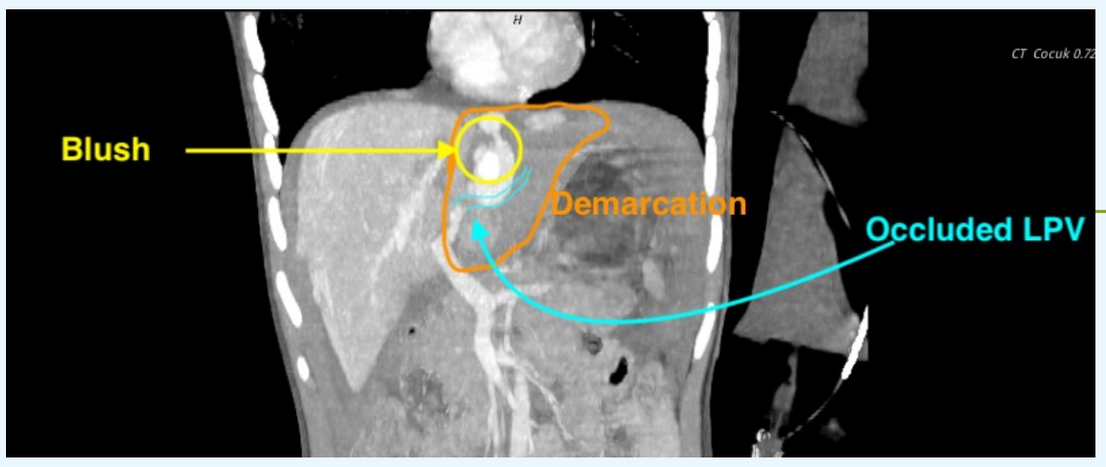

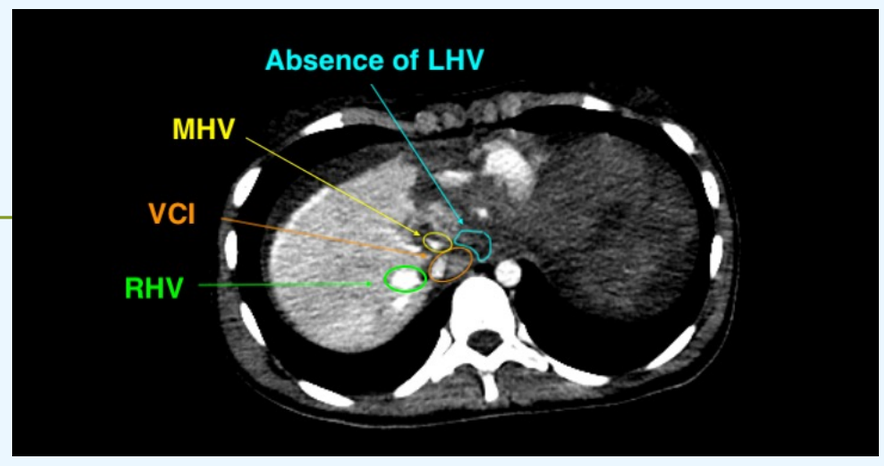

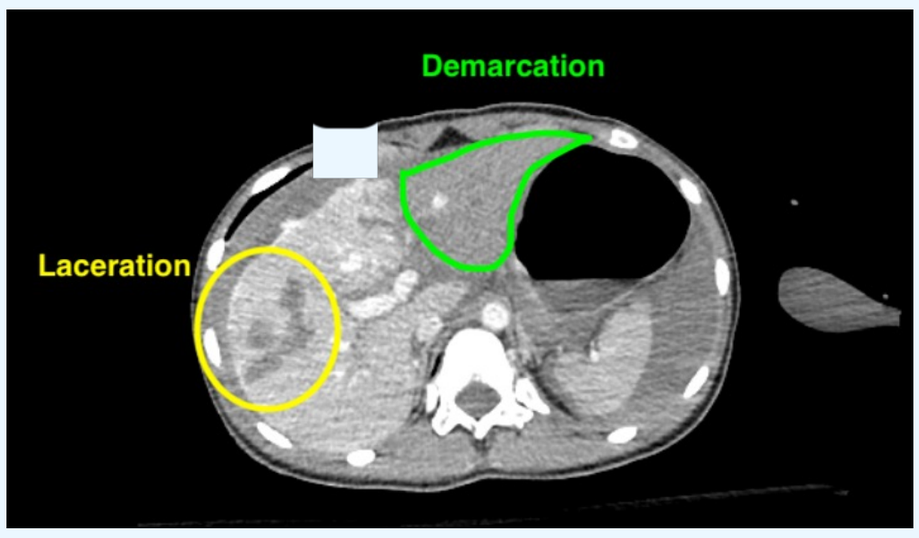

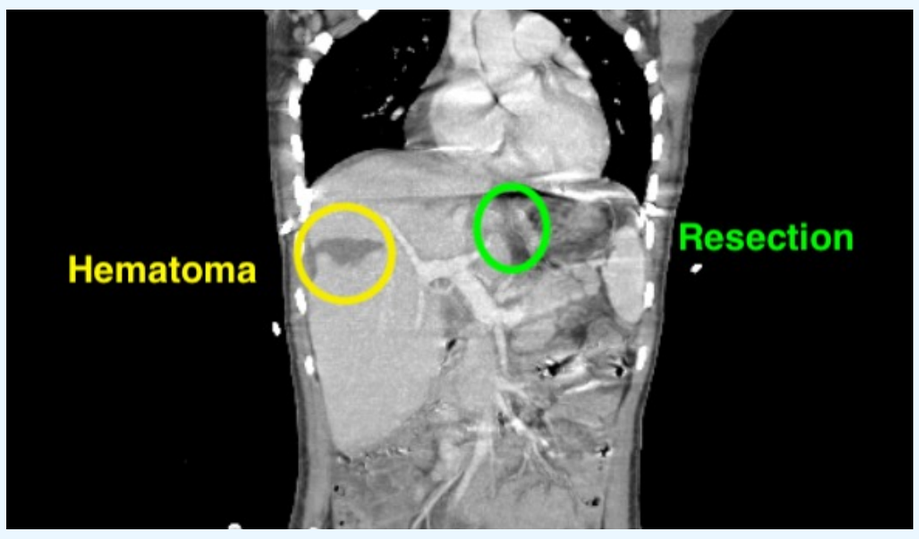

We performed left lateral sectionectomy suturing the left hepatic vein stump, ligated left portal vein and left hepatic artery using clips under Pringle's maneuver. After 48 hours, the patient's acidosis and coagulopathy improved, she was taken to the operating theatre again to perform re-laparotomy.

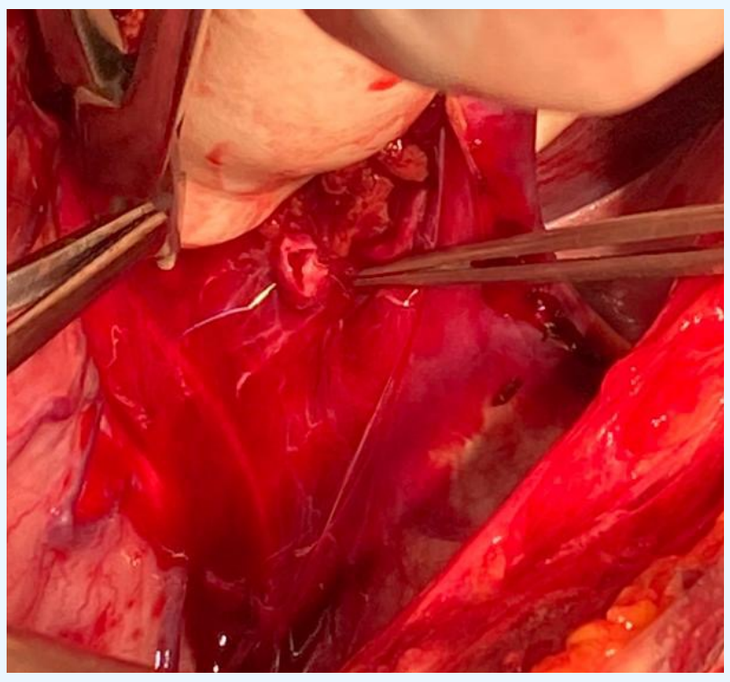

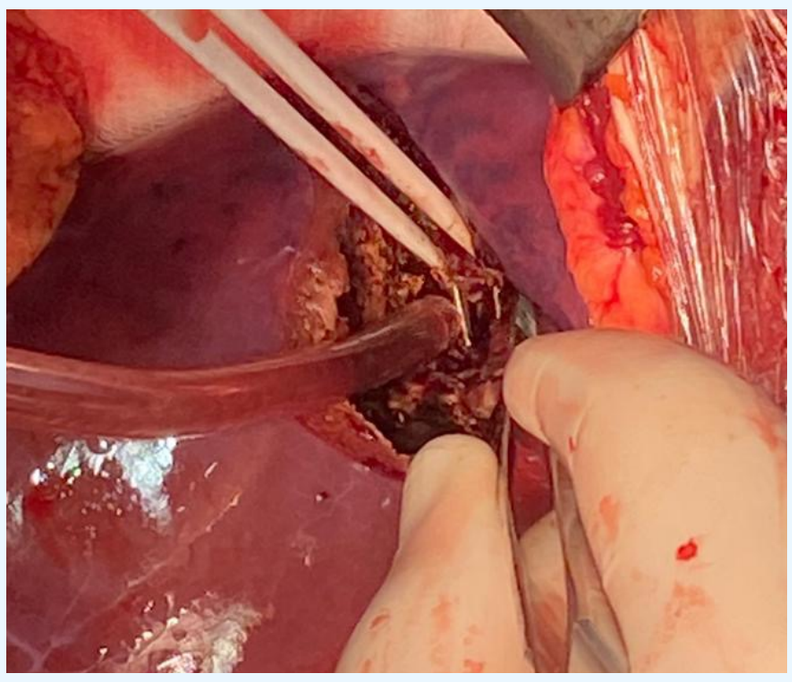

She was discharged on day 28.

1-year follow-ups were uneventful.

Conclusions:

Techniques used to control bleeding are closely tied to surgical skills, and they must be suitable for the damage, patient, and available support facilities.

Exposure is crucial. It is essential to implement automatic extractors.

If there is a lethal triad, damage control surgery should be performed. In cases of intractable, acute hemorrhage, Pringle maneuver may be useful.

The surgeon must constantly remember intensive vascular control techniques, if serious liver damage does not respond to packing. Collaboration with experienced hepatopancreaticobiliary surgeons is crucial for optimal outcomes.