Evaluating the diagnostic value of contrast enema in Hirschsprung's disease

B Murat[1], G Gercel[1], SG Bozbeyoglu[2], M Çaglar[1], A Canmemis[1], E Uzun[1], Ç Ulukaya Durakbaşa[1]

Istanbul Medeniyet University, Faculty of Medicine, Departments of Pediatric Surgery[1] and Radiology[2]

ISTANBUL MEDENIYET UNIVERSITY

PURPOSE: To assess the diagnostic sensitivity of the rectosigmoid index (RSI) and radiologic transition zone (TZ) on contrast enema (CE) in Hirschsprung's disease (HD)

METHOD: 2006-2025, retrospective review
RSI ≤1 was considered diagnostic for HD
Radiologic TZ levels were compared to histopathological TZ

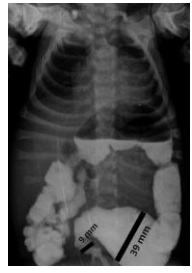

RSI: 0.23

RESULTS:

50 males (79.3%), 13 females (20.7%)
Median age: 11m (1m-10y)

- RSI (≤1): 47 (74.6%) patients
- RSI (>1): 16 (25.4%) patients

	n	%
<1 year	34	54
1-3 years	23	36.5
>3 years	6	9.5

	RSI ≤1 (n)	Sensitivity (%)
Rectosigmoid (n=49)	39	79.5
Long-segment (n=8)	3	37.5
Total colonic (n=6)	5	83.4

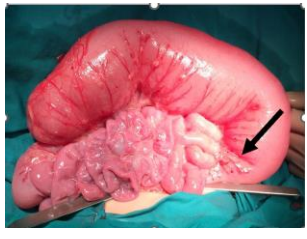

RSI: 1.12

Contrast Enema (TZ):
Splenic flexure

Histopathological evaluation (TZ):
Transverse colon

	No TZ identified on CE (n)	TZ identified on CE (n)		Sensitivity (%)	Positive Predictive Value (PPV) (%)
		Correct	Incorrect		
Rectosigmoid HD (n=49)	9	39	1	79.6	97.5
Long-segment HD (n=8)	1	7	0	87.5	100
Total colonic HD (n=6)	3	0	3	0	0
Total (n=63)	13	46	4	73	92

CONCLUSION:

- The diagnostic accuracy of RSI and the TZ on CE is limited
- The high PPV observed in cases where the TZ can be clearly identified suggests that contrast studies may be a valuable tool for surgical planning