

A RARE ANOMALY IN A CHILD: CONGENITAL H-TYPE RECTOVESTIBULAR FISTULA

Savalan Khammadli, Ali Ekber Hakalmaz, Ayşe Kalyoncu Uçar*, Pınar Kendigelen**,
Mehmet Eliçevik, Rahşan Özcan

Departments of Pediatric Surgery, *Radiology, **Anesthesiology
Cerrahpaşa Faculty of Medicine, Istanbul University-Cerrahpaşa

Clinical Presentation

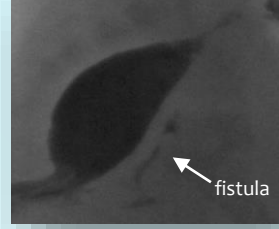
Two months old female
Urinary tract infection
Fecal discharge from the vagina

Diagnostic Evaluation

Anatomical location of urethra
vagina, anus

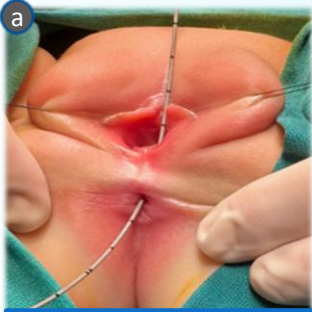
Pelvic MRI normal

Opaque Enema

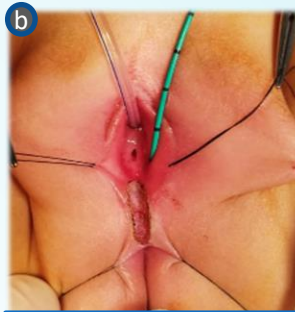


Cystoscopy
Vaginoscopy
Rectoscopy
Anal stimulation

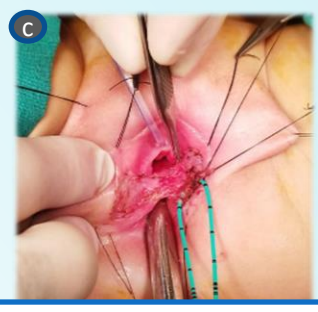
Surgical Management:



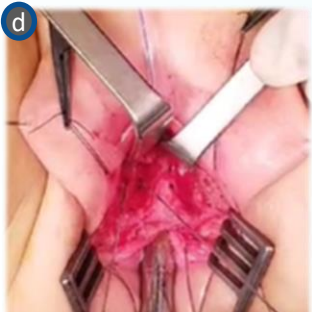Catheterization of the fistula



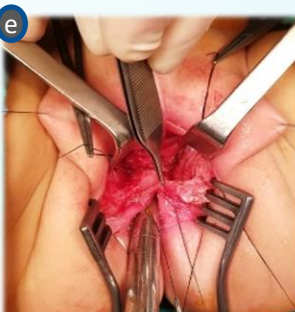
Anterior sagittal approach



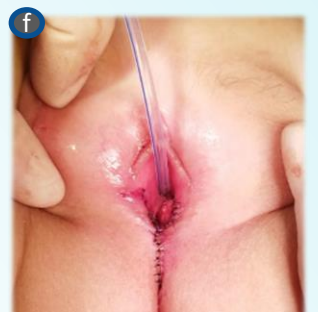Intersphincteric plane and
identifying the fistula tract



Complete separation of the
vagina and rectum



Excision of the fistula tract



Perineal repair

Conclusion:

- Vaginal fecal discharge and urinary tract infections may indicate an H-type fistula.
- A physical exam and imaging are essential for diagnosis.
- Surgery involves excising the fistula after complete separation of the rectum and vagina while preserving the levator plane.

